

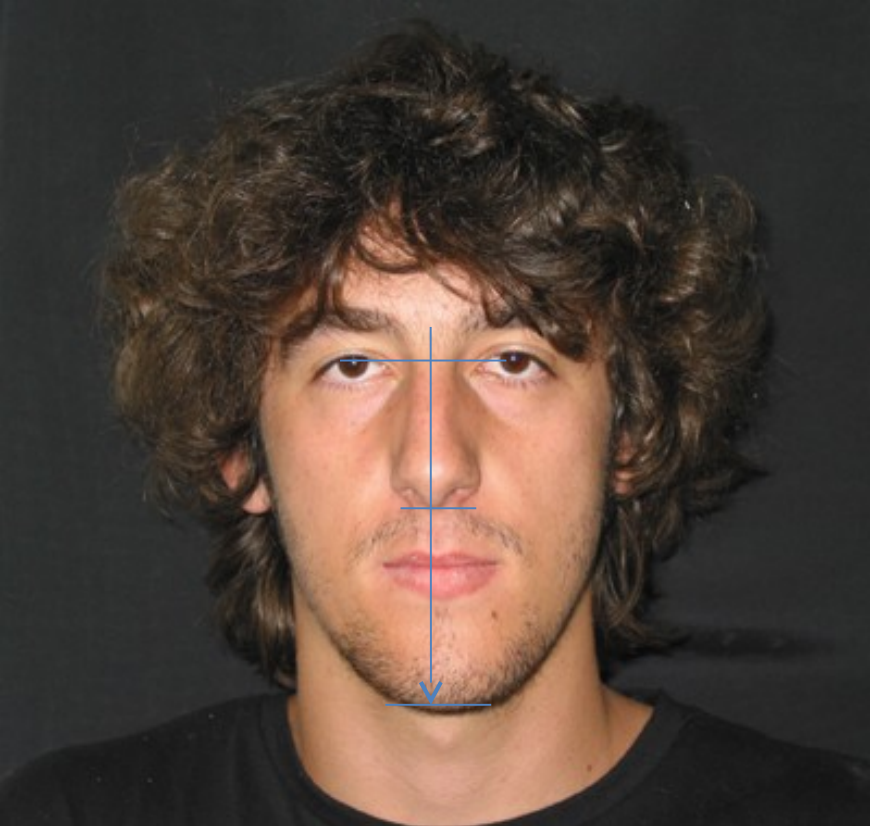
CARLOS ASUNCION TARREGA

PREPARACION PREQUIRURGICA

6-2012

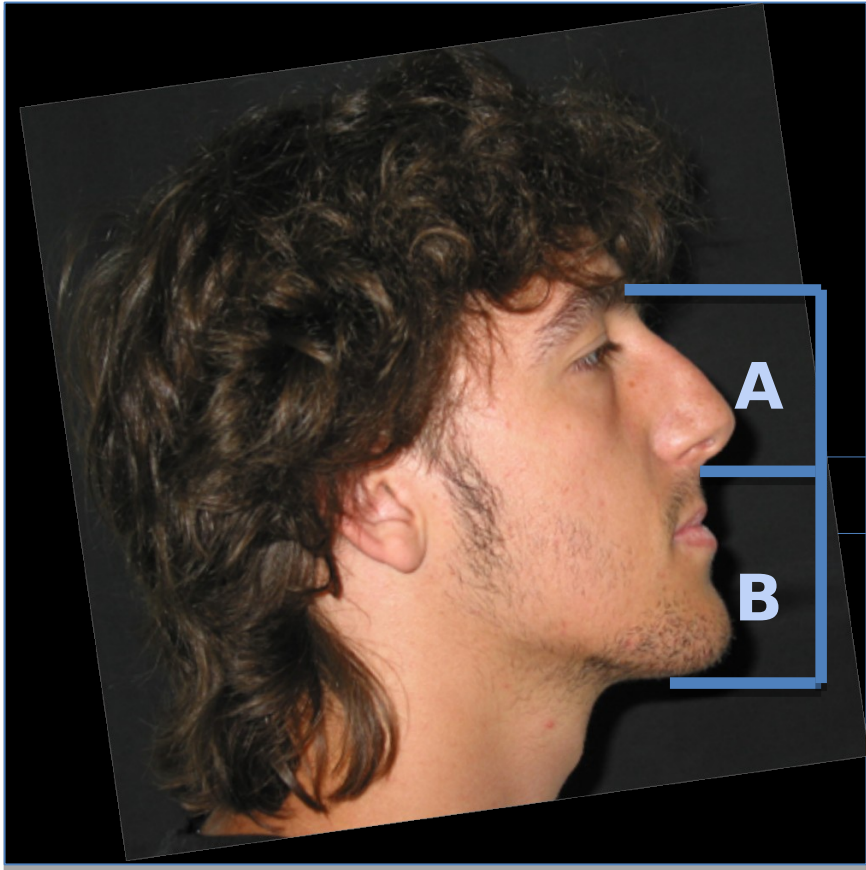
Dra. Laura Di Giuseppe


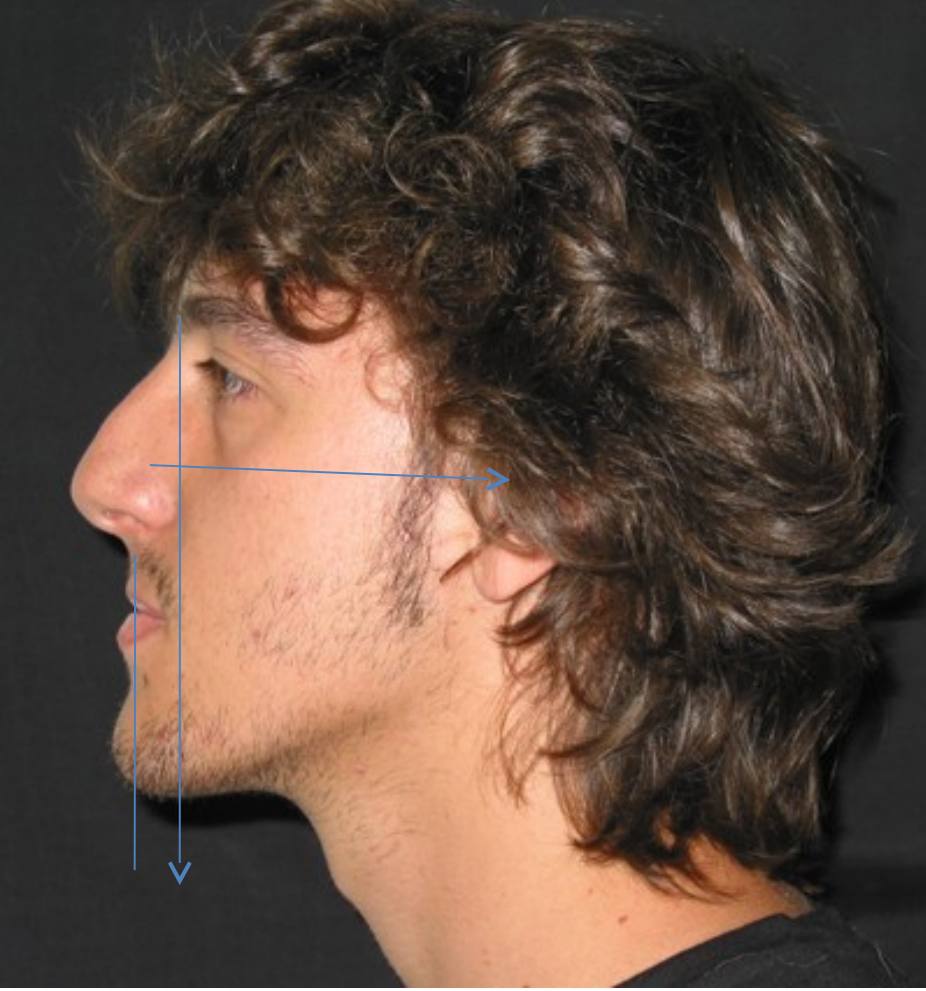

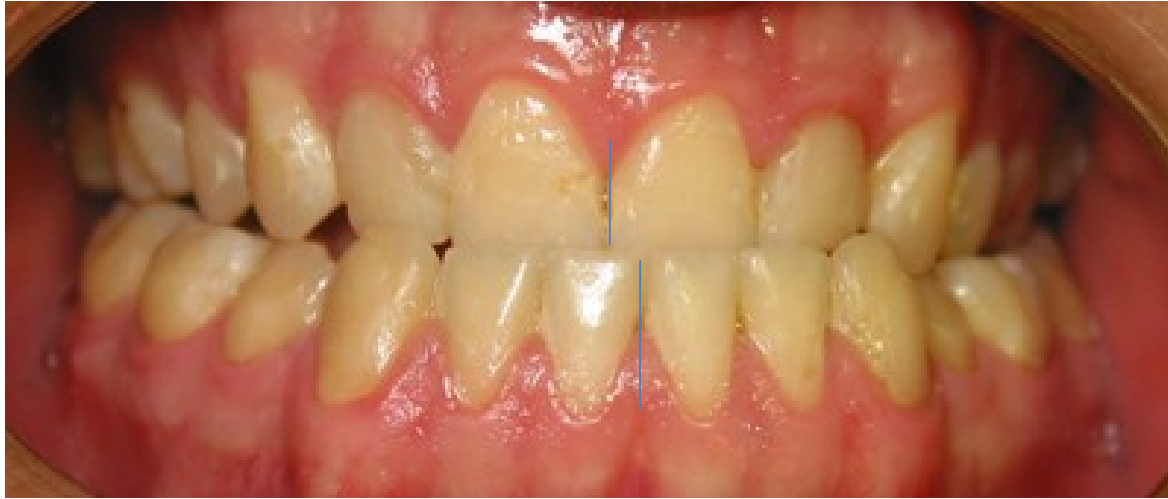




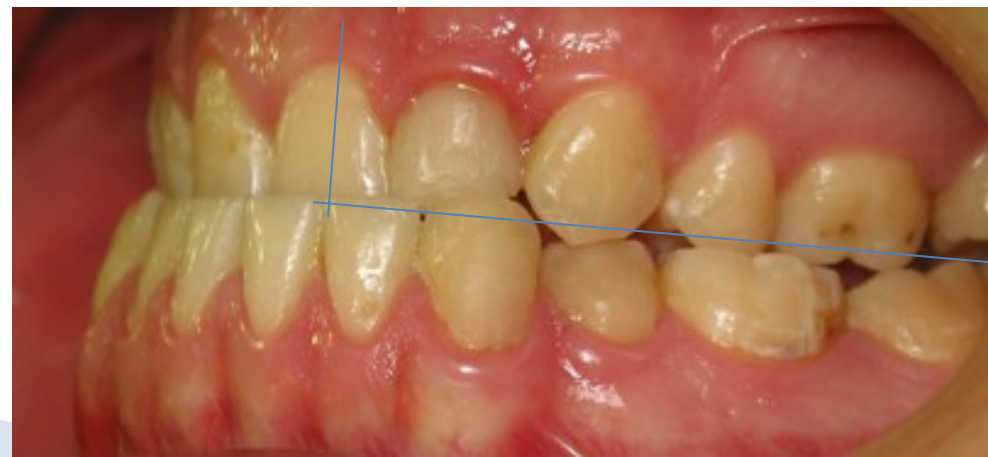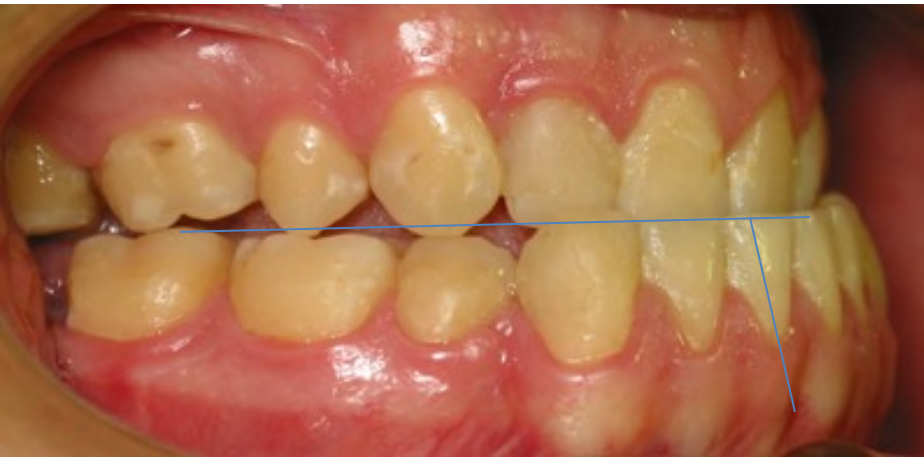A=B

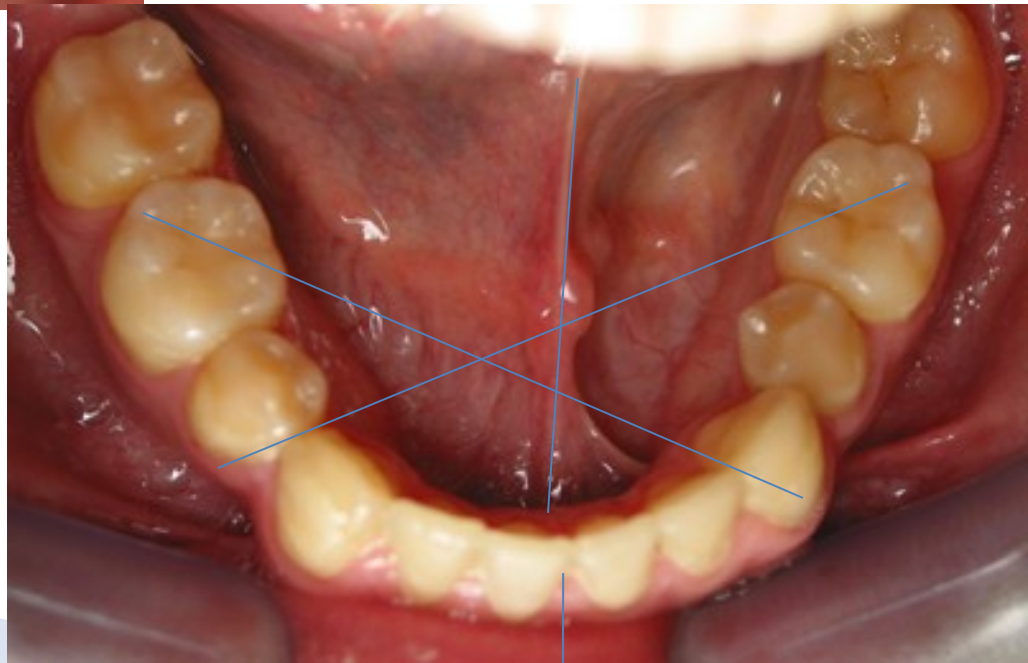
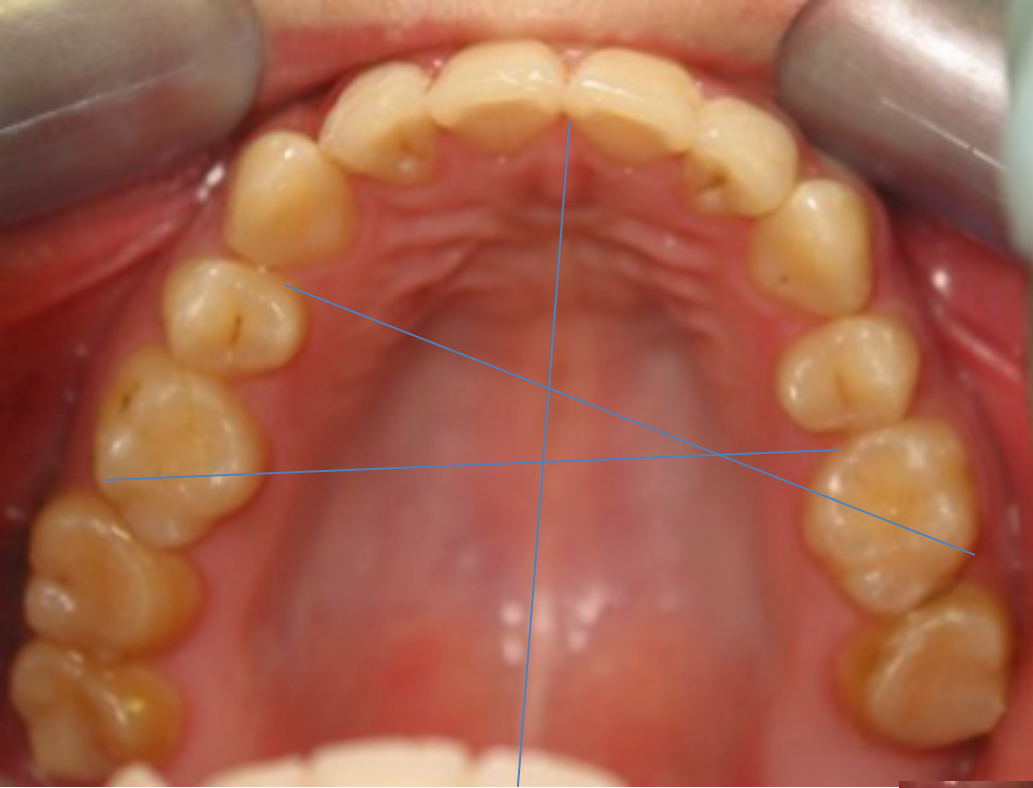


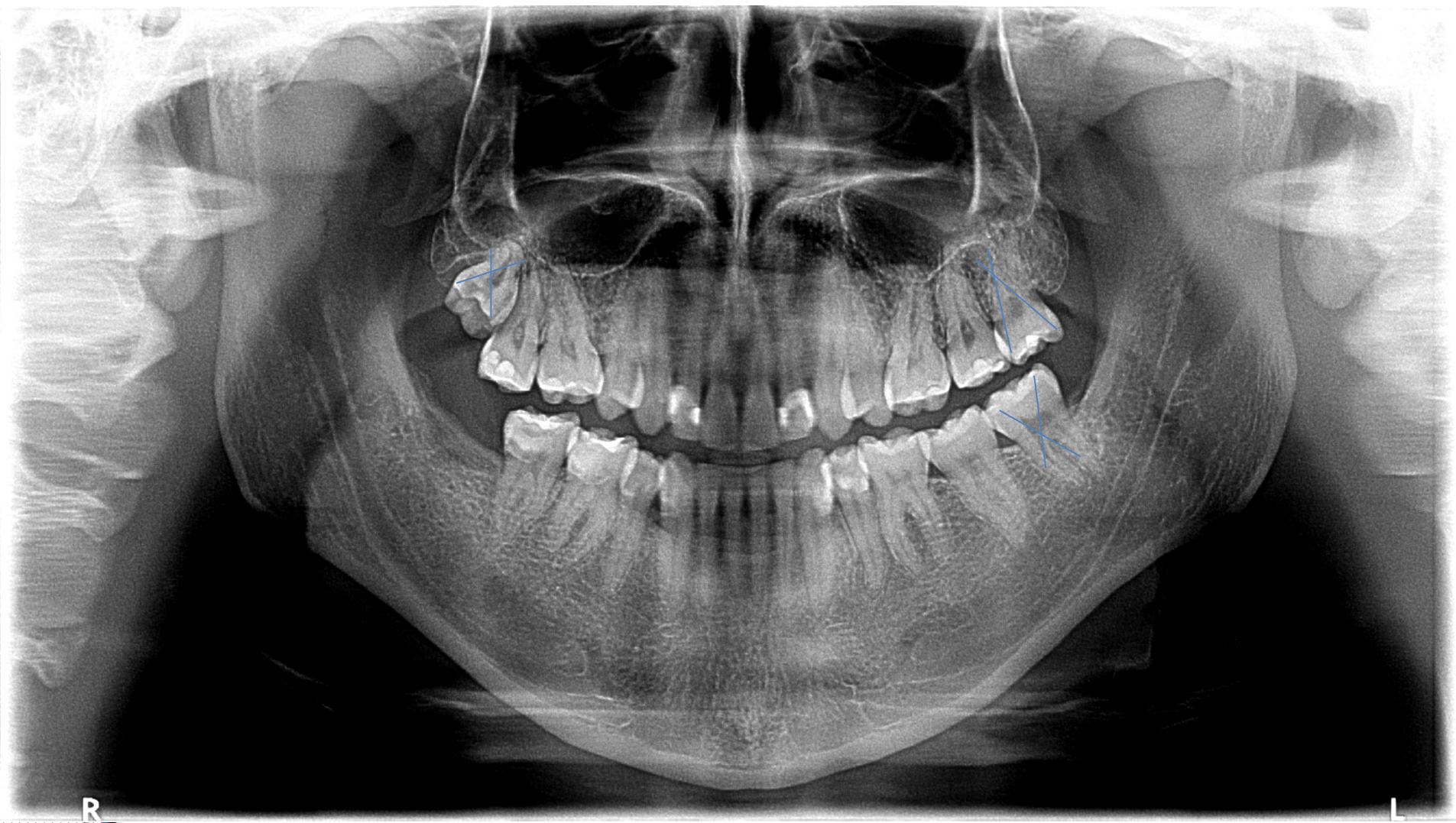




6-12 INICIO
11-PLANO OCCLUSAL :77°
41-PLANO OCLUSAL :78

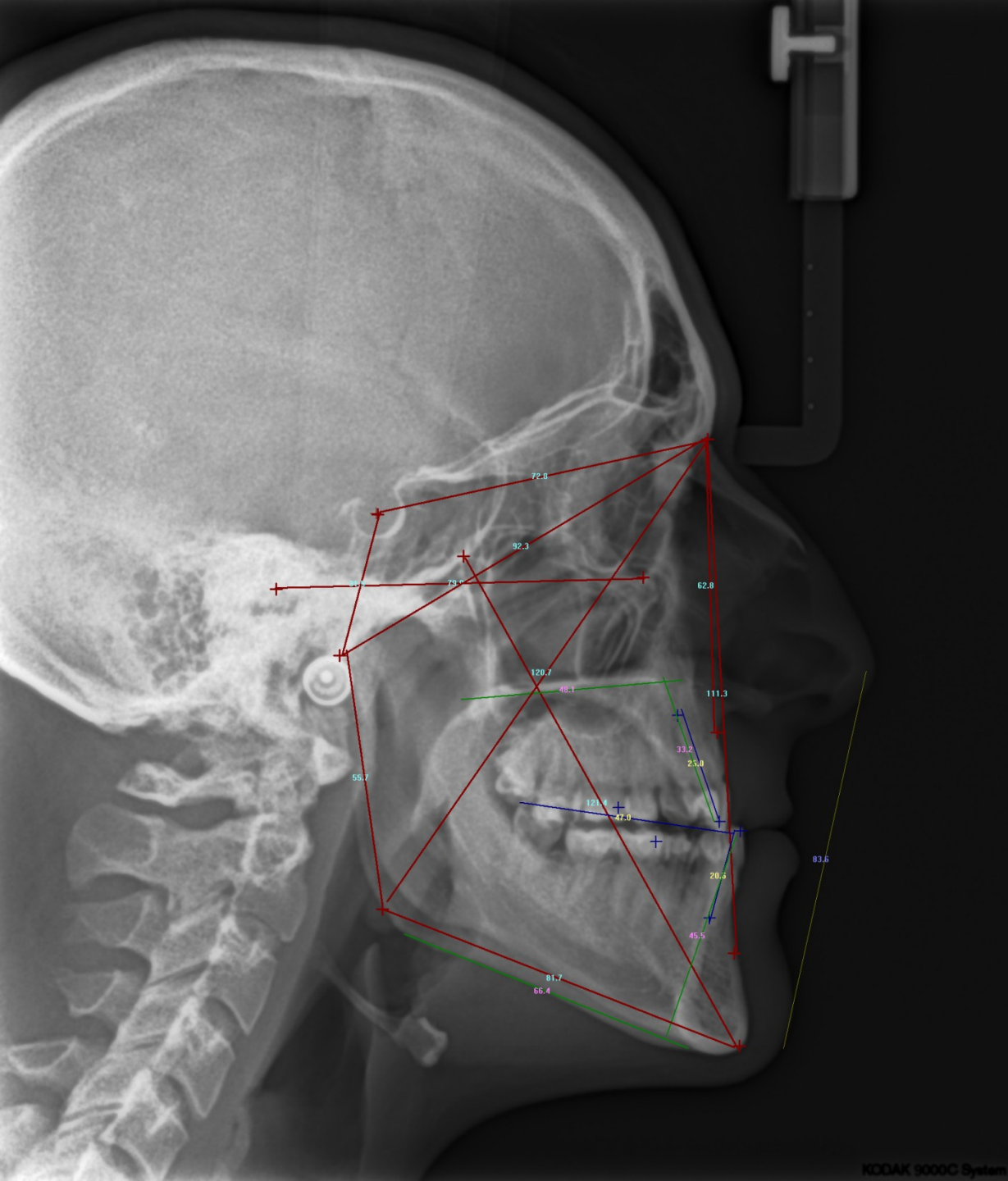






R

L

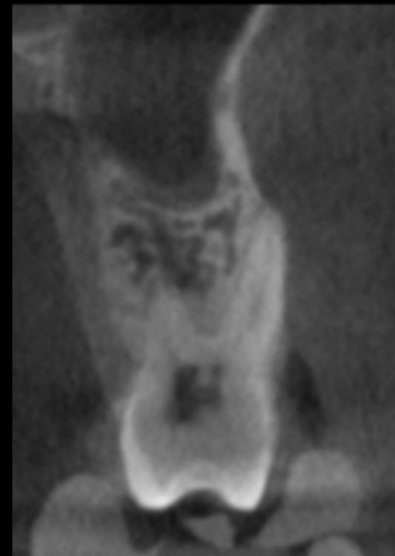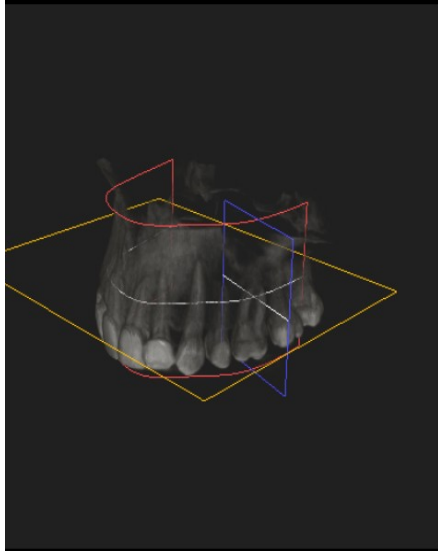

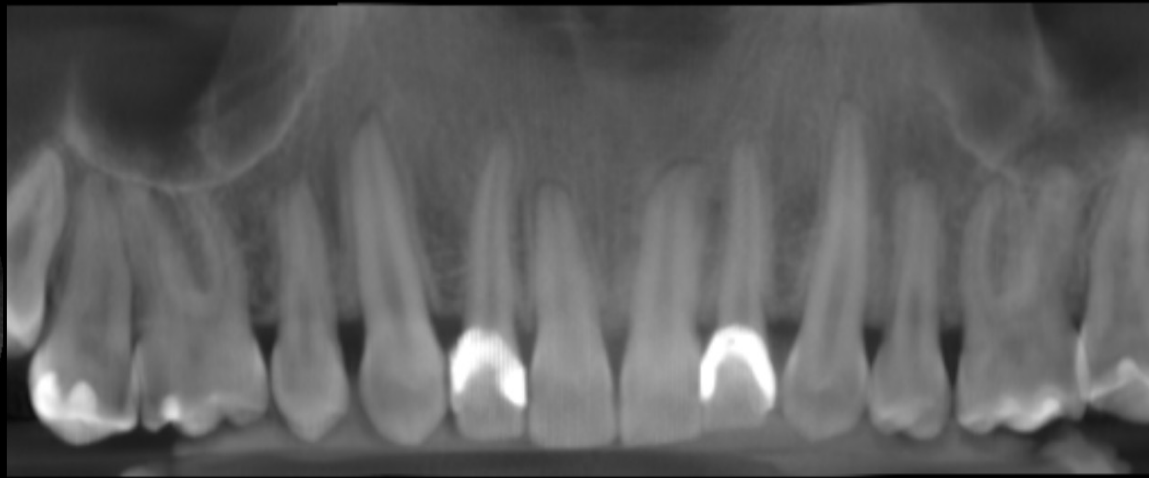
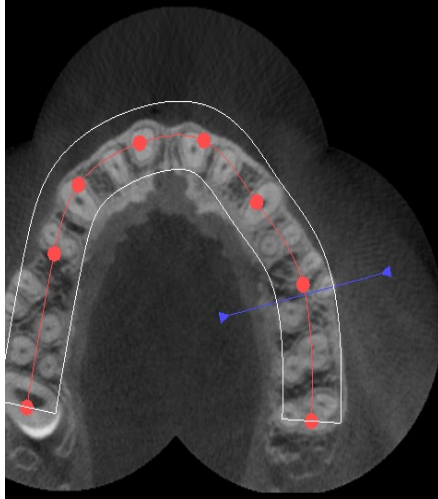INICIO 6-12

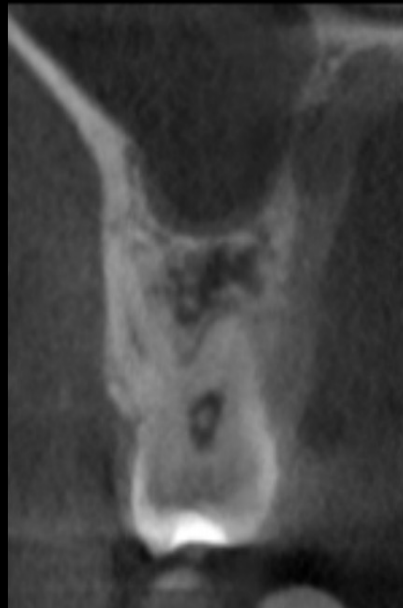
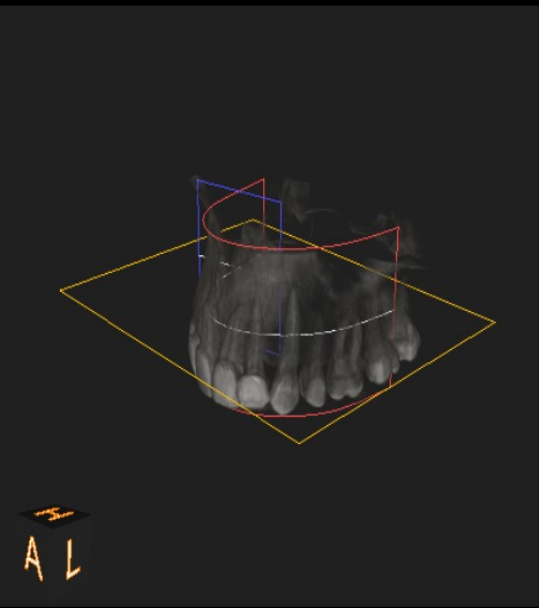
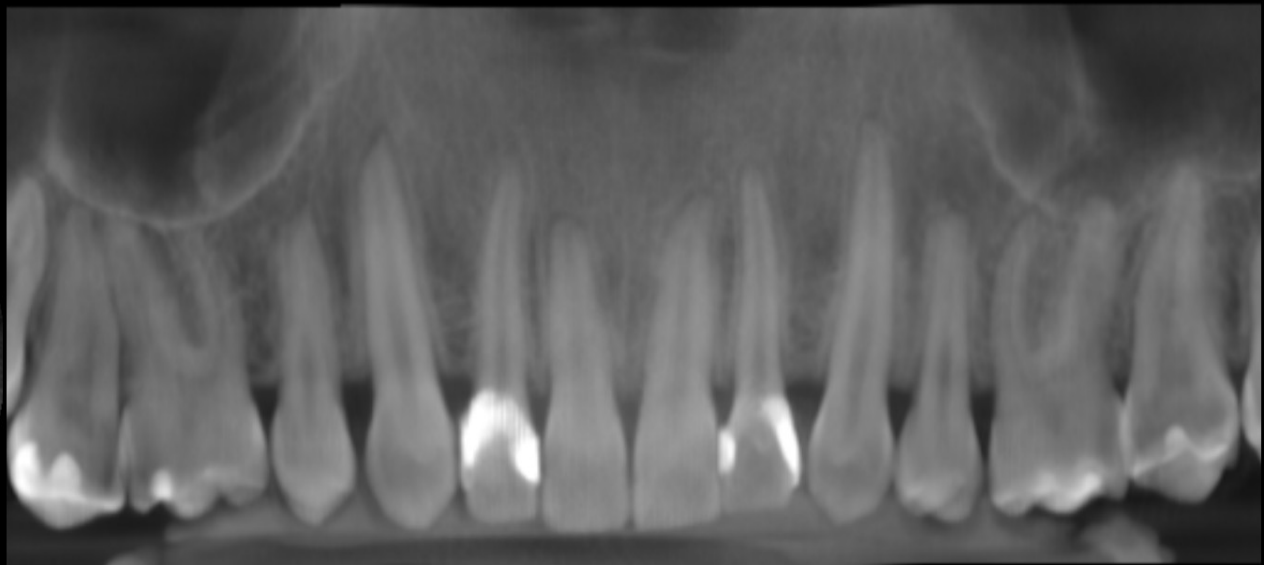
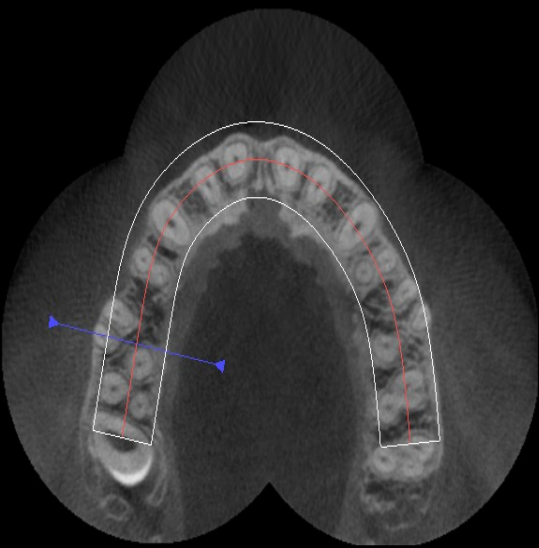
11-PLANO OCCLUSAL :
77°57°

41-PLANO OCLUSAL :
78°65°

ENAP-ENP- 11 102°110°



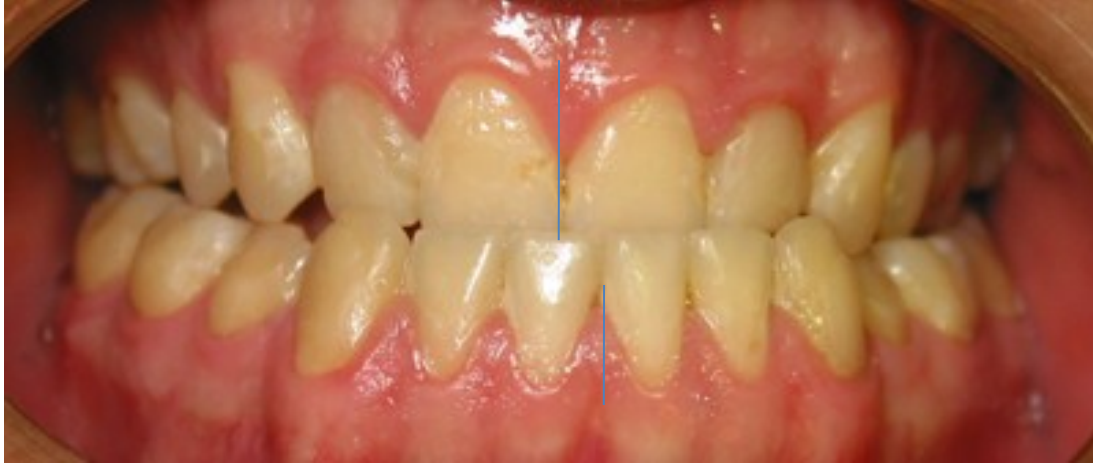Posicion 3D del 26



Posicion 3D del 16

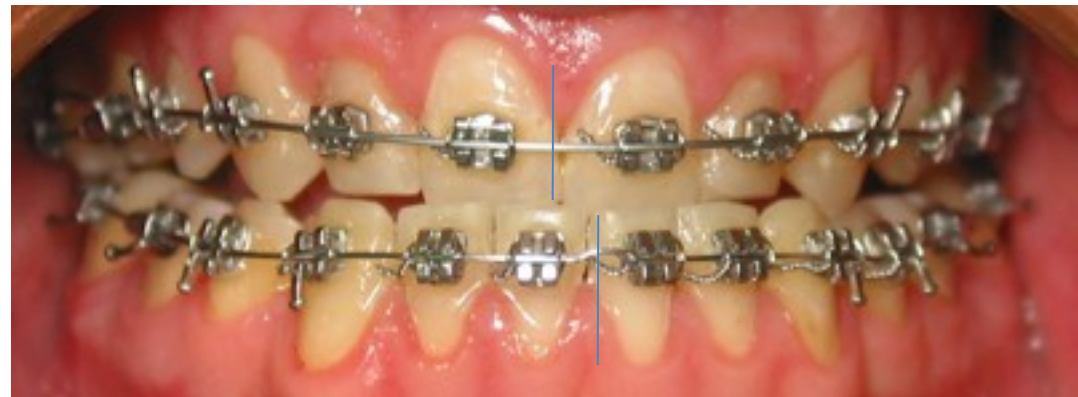
Preparacion terapeutica previa al cimentado

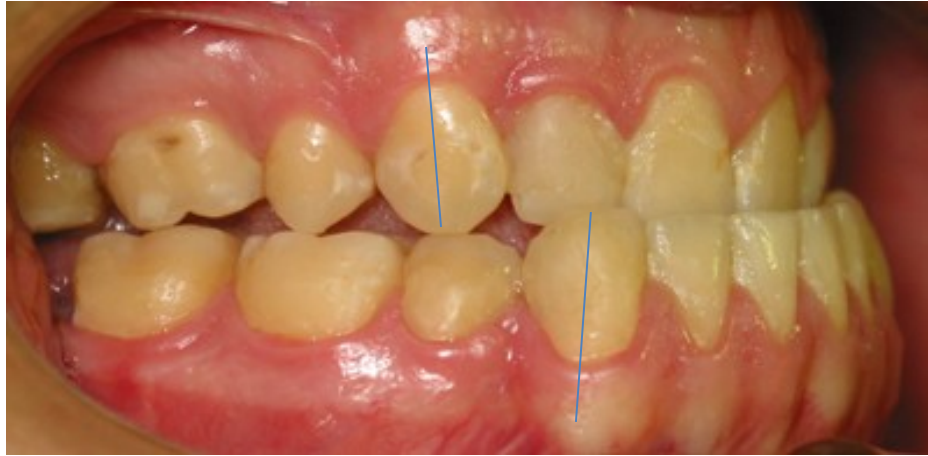- **Enseñanza de tca
de cepillado**
- **Reparacion manchas
blancas**
- **Topicacion con fluor**
- **se indica pasta alto
% fluor**



INICIO

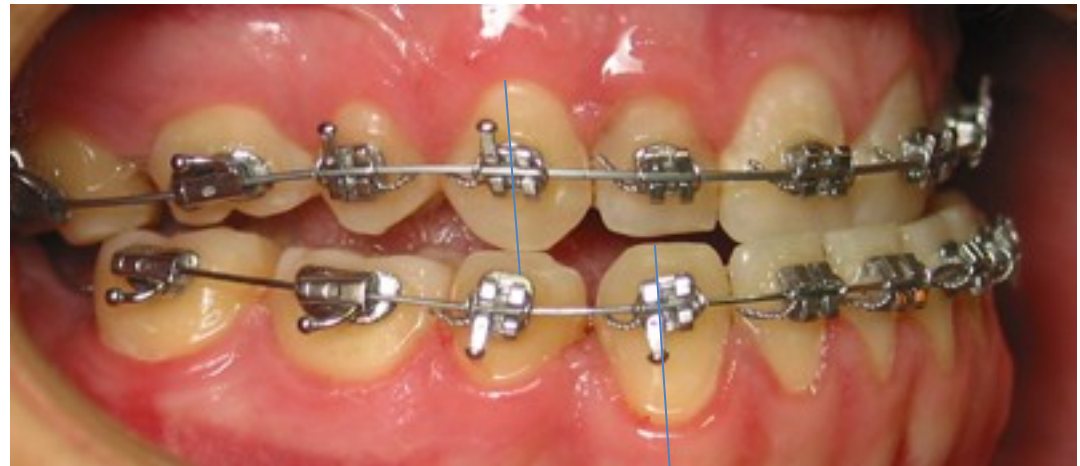
11-12

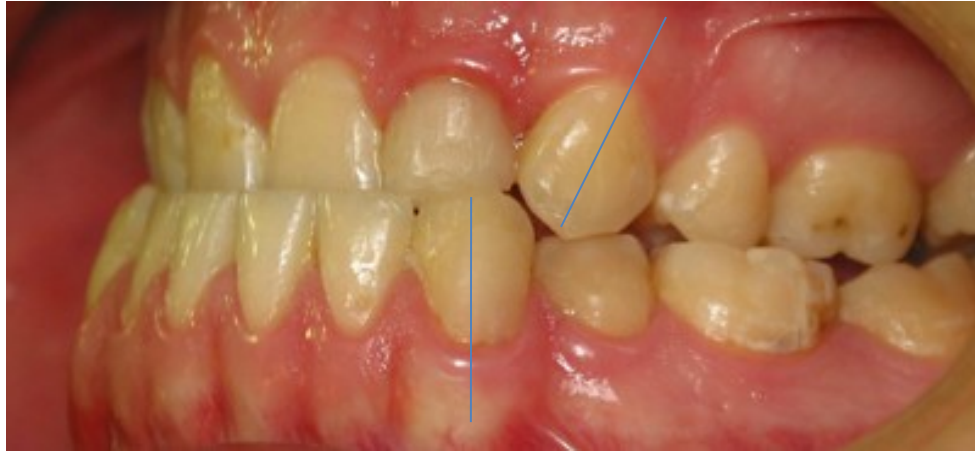



INICIO

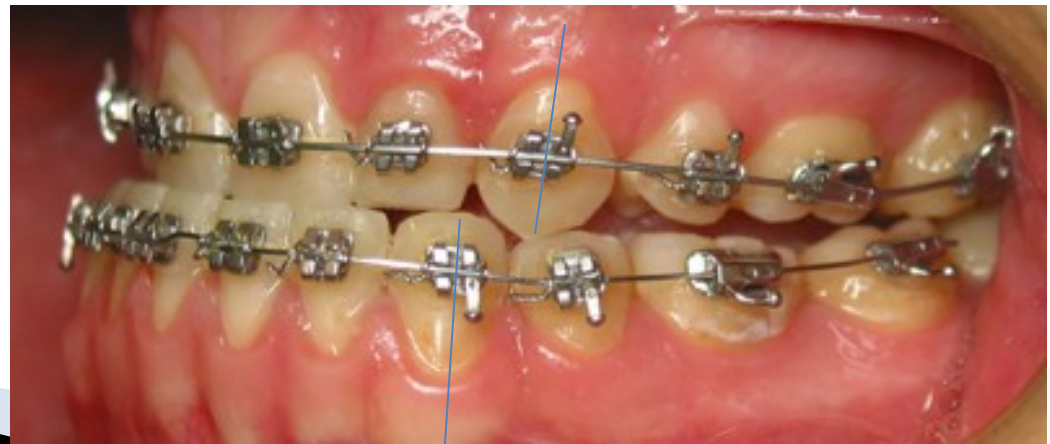
11-12

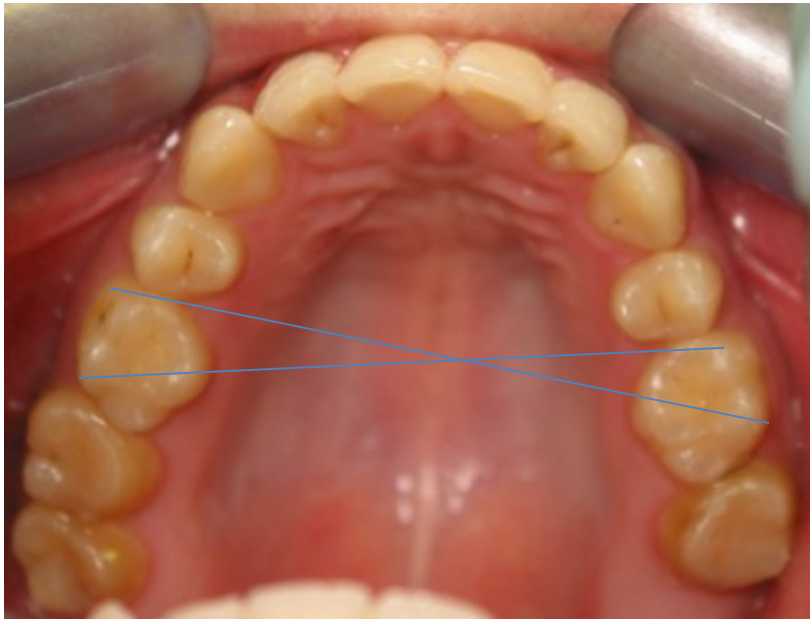




INICIO

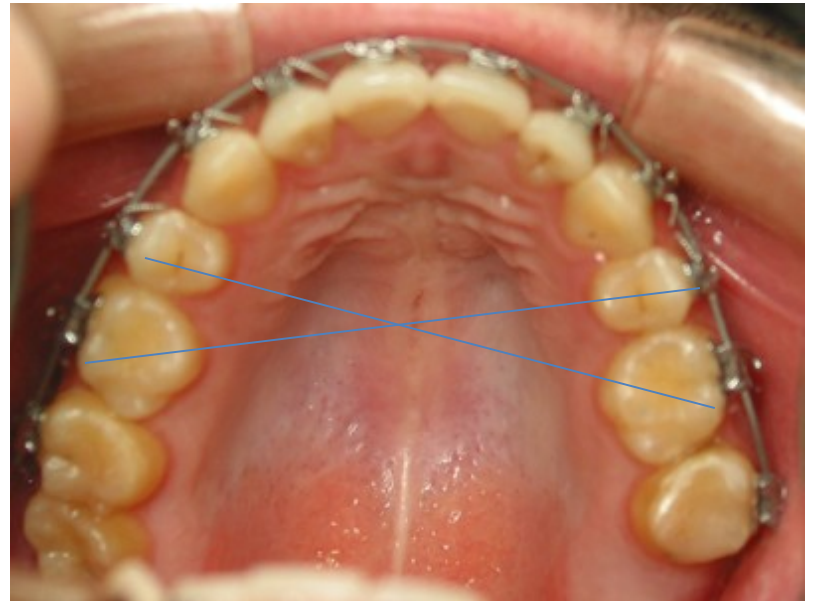
11-12

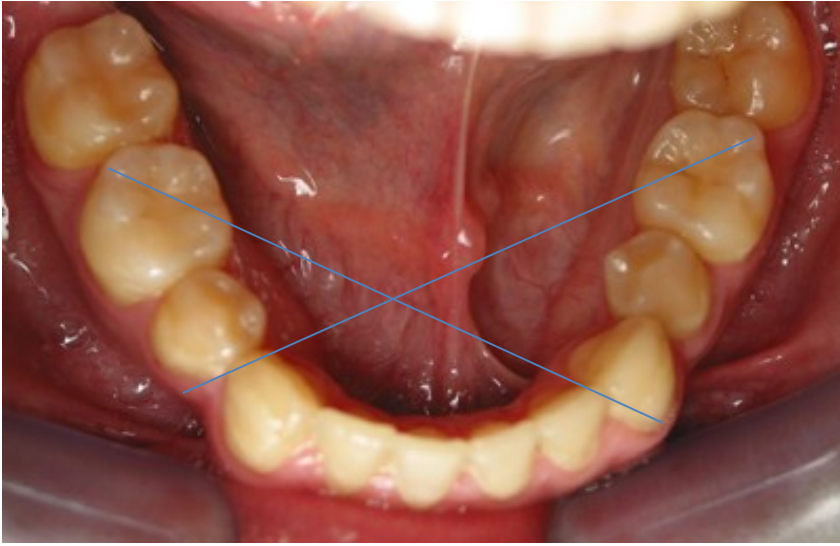




INICIO

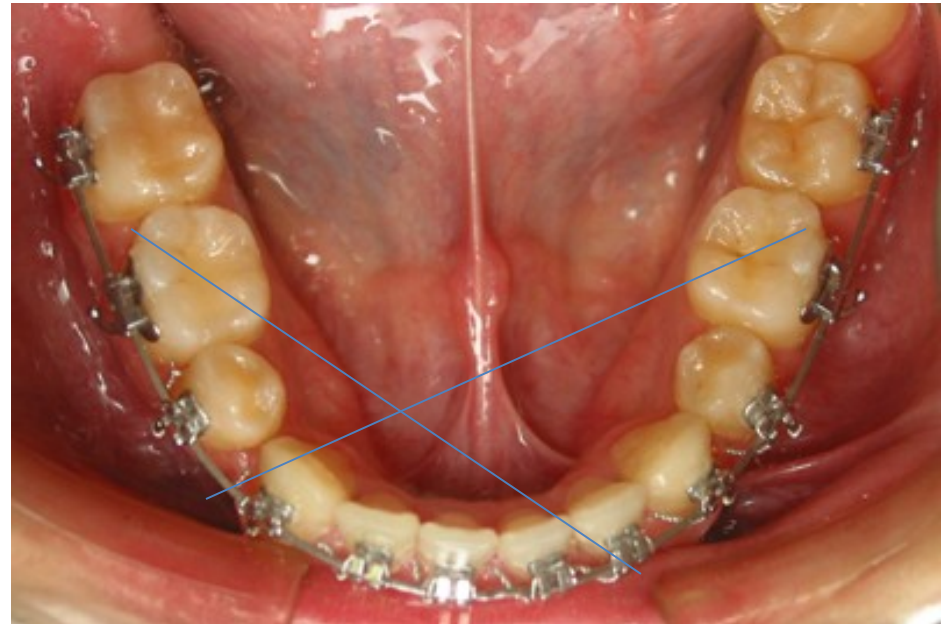
11-12

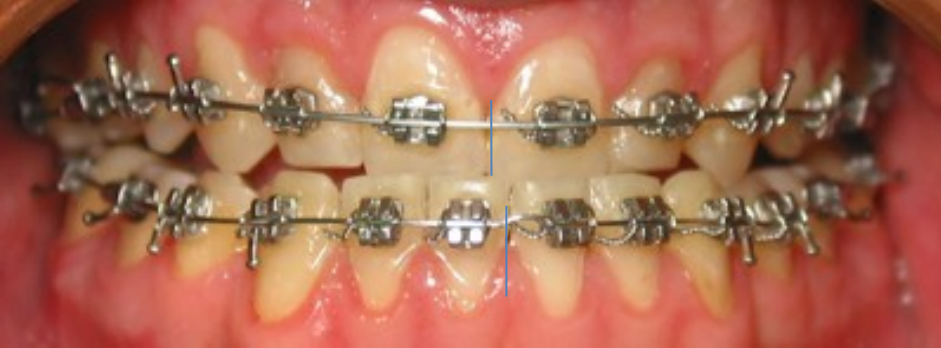



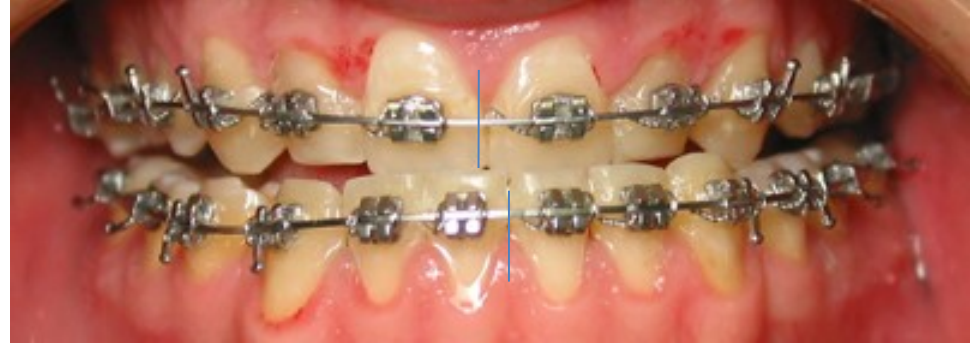INICIO

11-12

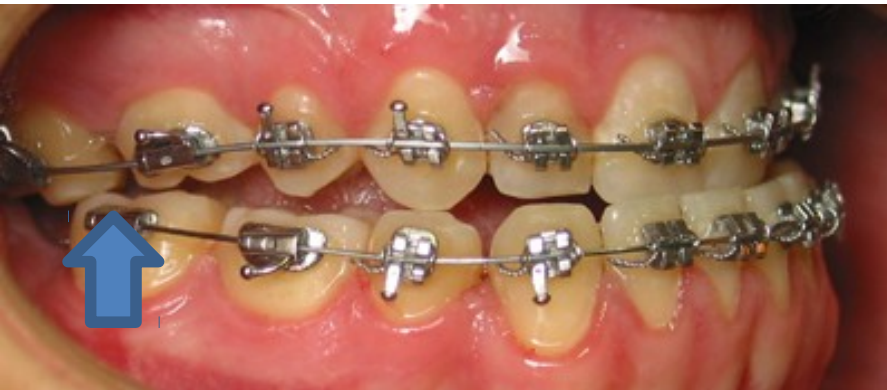



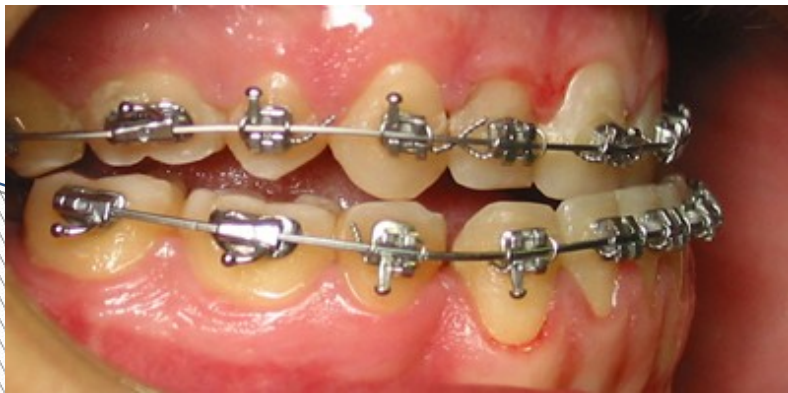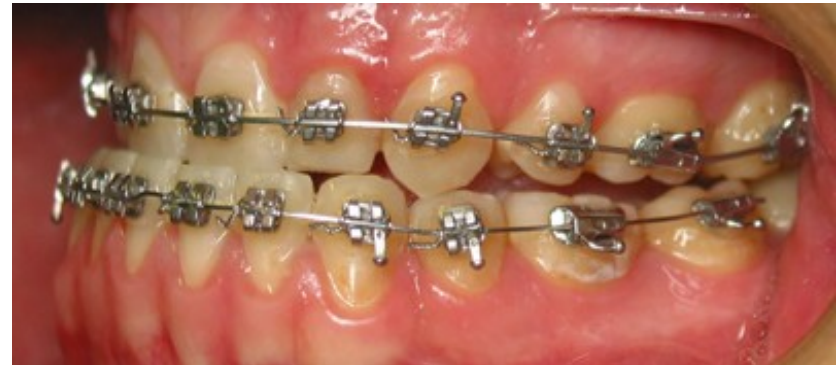11-12



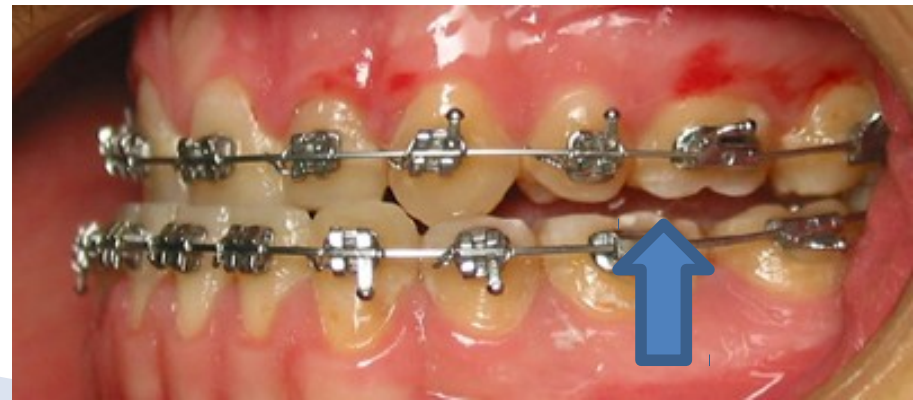
1-13

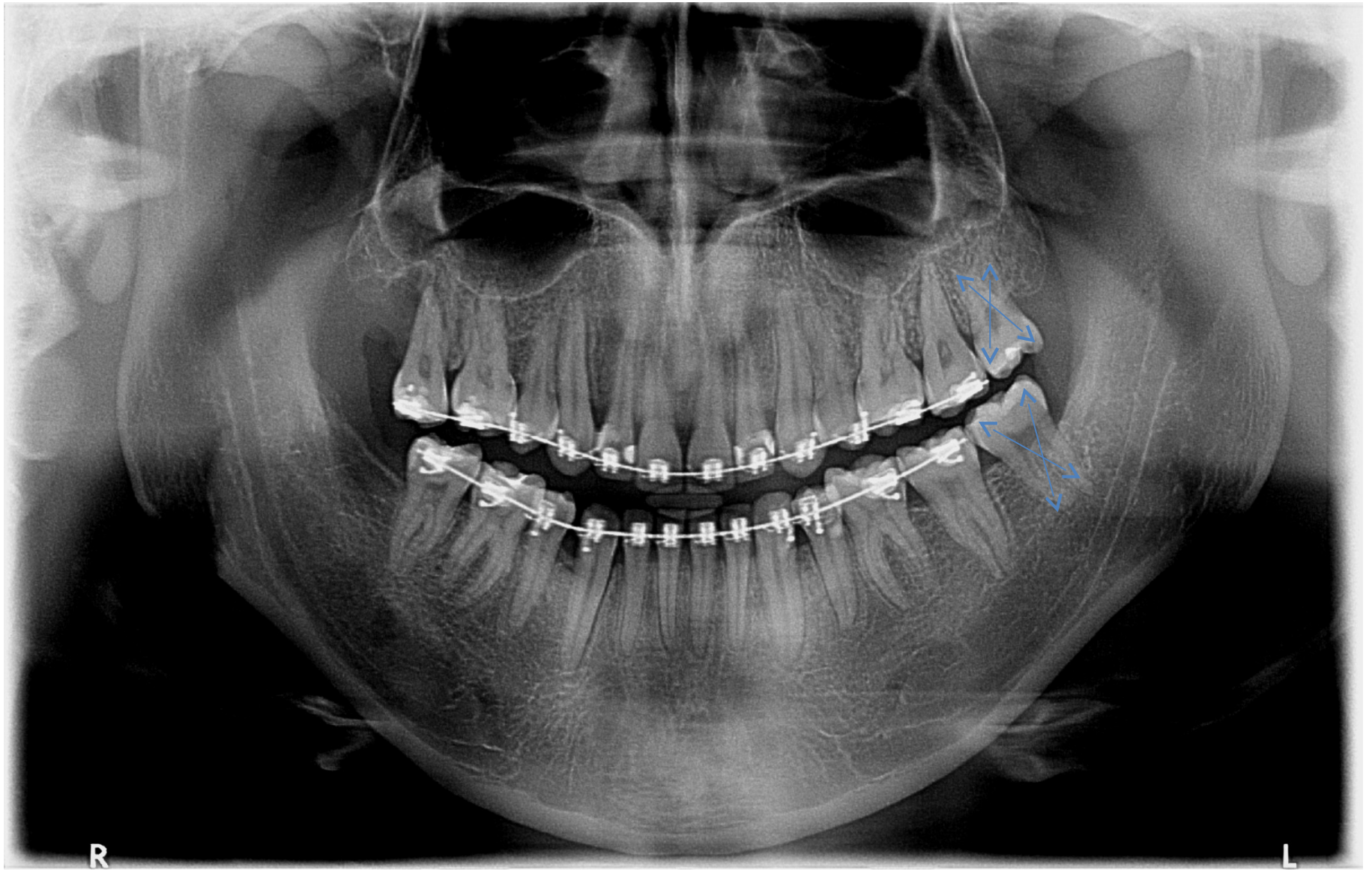


11-12

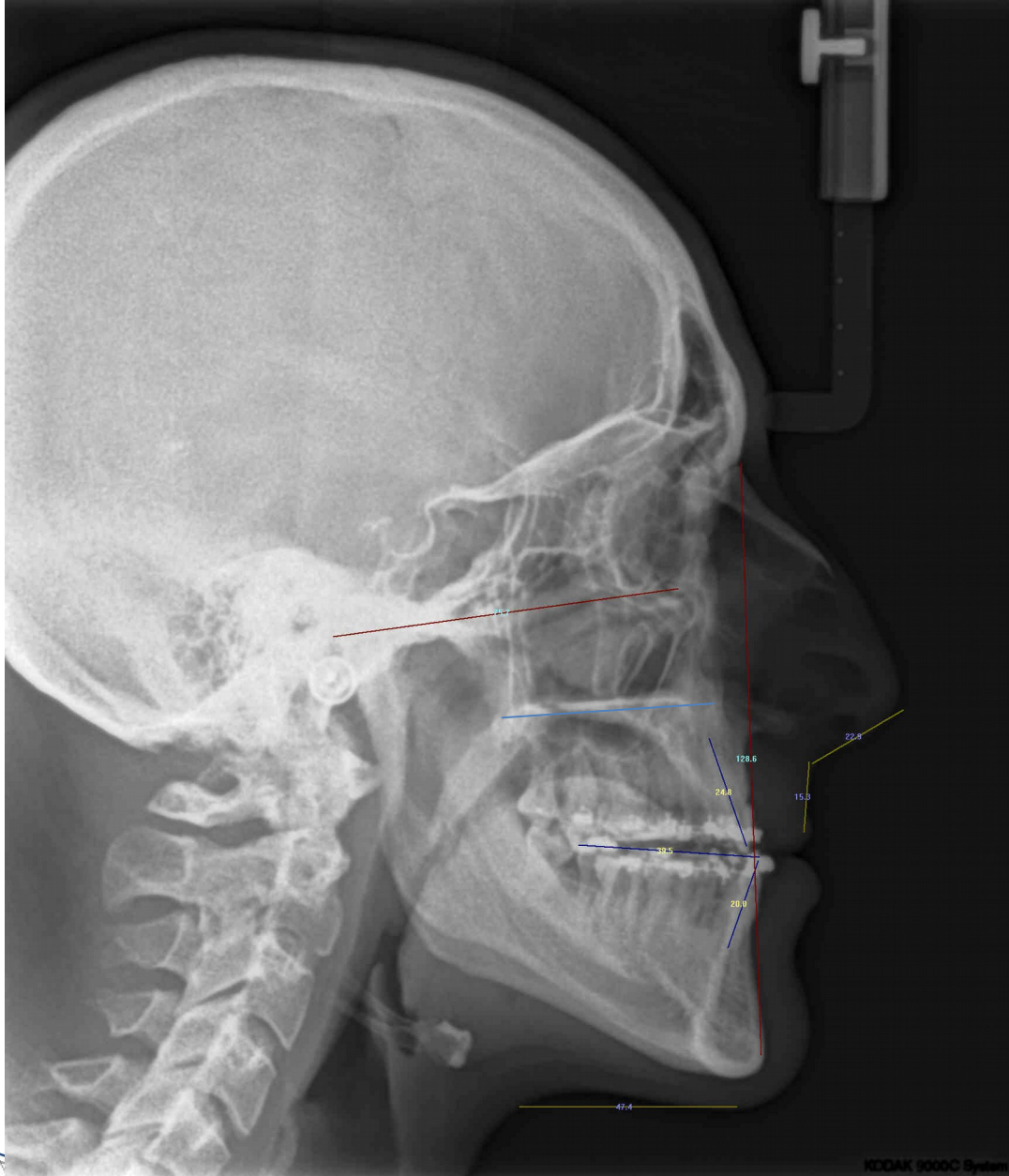


1-13





1-13



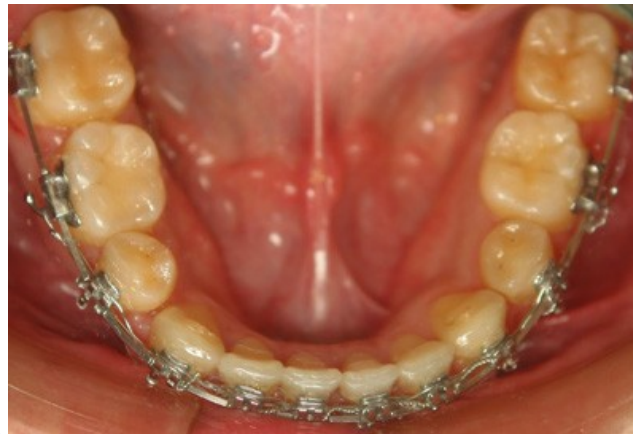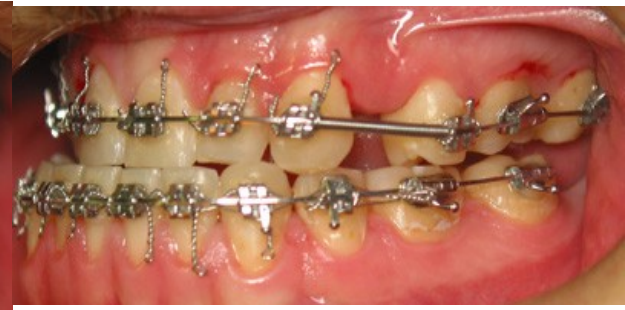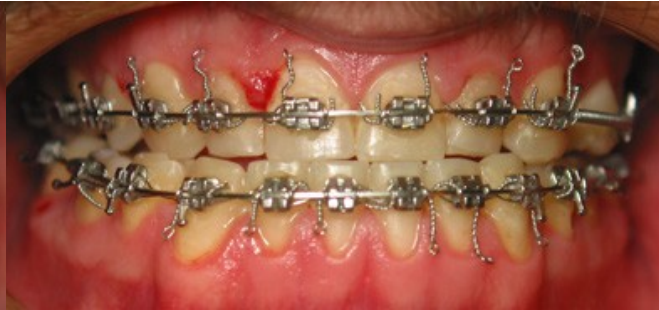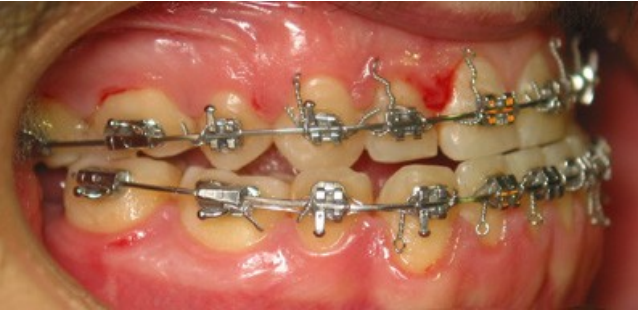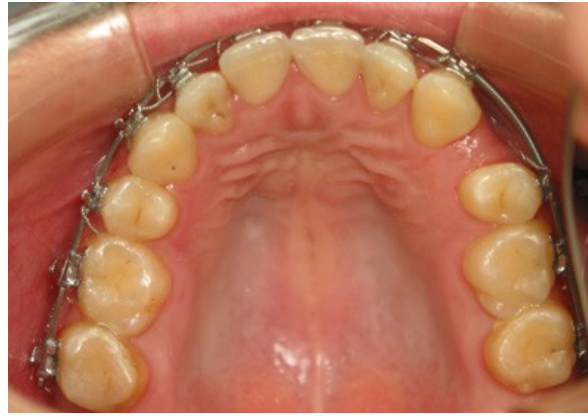1-13

11- AL PL OCLUSAL $72^{\circ}57^{\circ}$

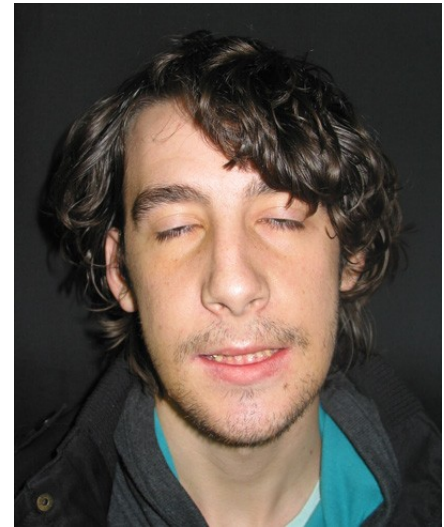
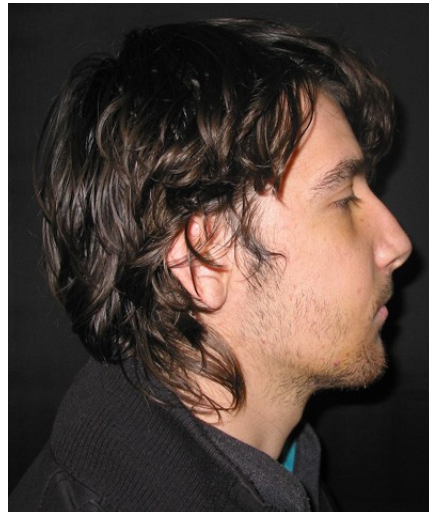
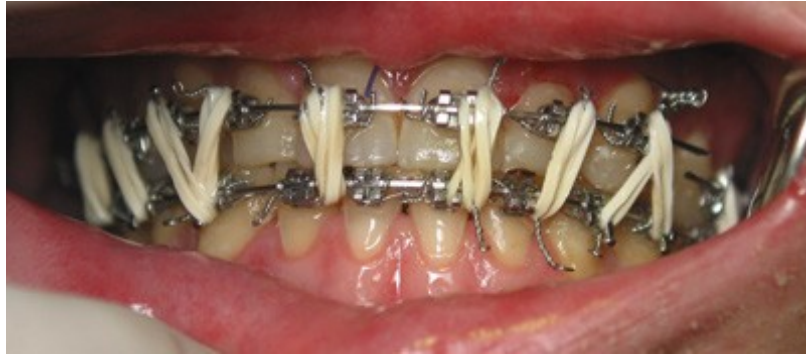41- AL PLANO OCLUSAL $66^{\circ}65^{\circ}$

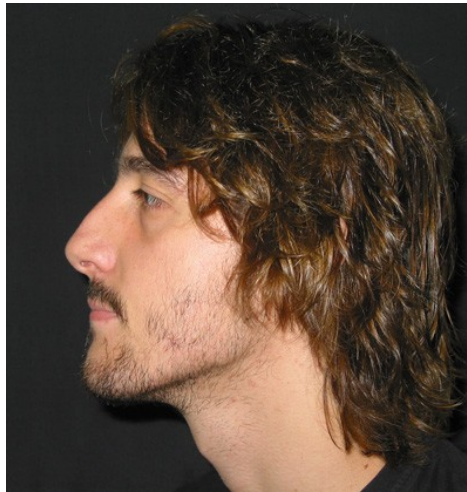ENA-ENP-11 $112^{\circ}112^{\circ}$

Prequirurgico
1-2014

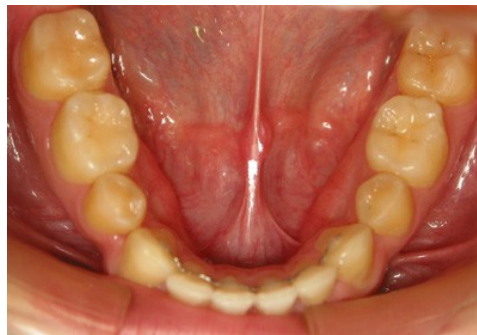
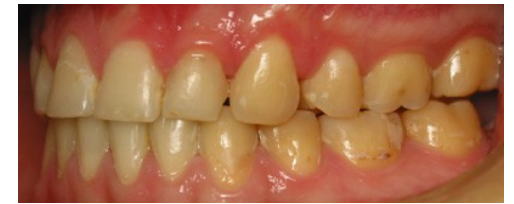
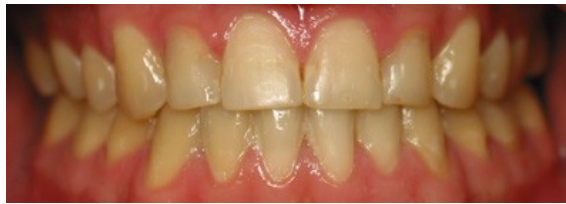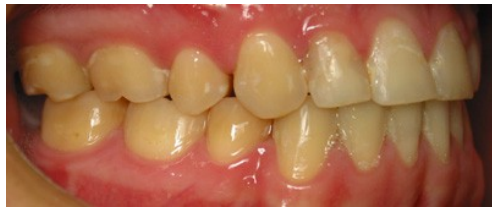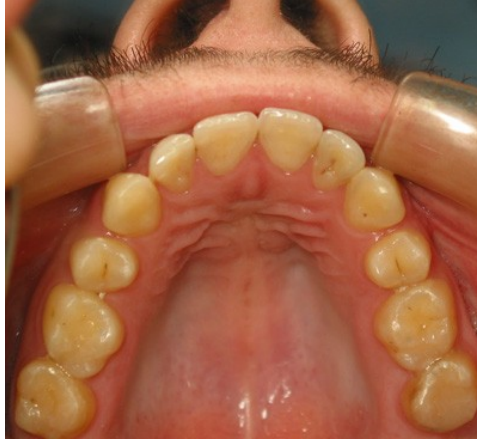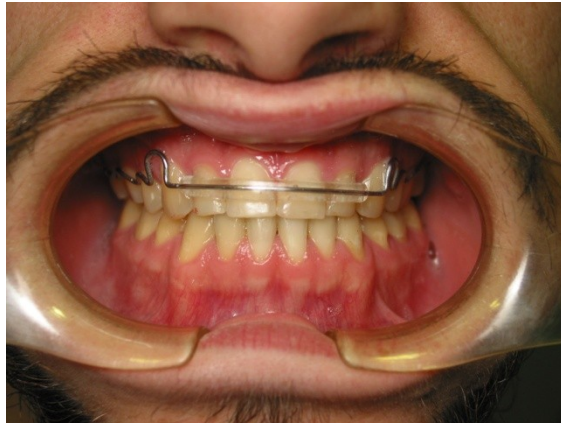Postoperatorio + 1 semana . (cirugía 21-1-2014)





Finalizacion +
ajuste oclusal
9.2014





Placa Jarabak, contencion pasiva.

